

JUST IN TIME

By Estelle Low

BACK TO NORMAL

David with an X-ray of his spine before surgery.

A little more than a year ago, chicken rice seller Mr David Chua could barely see the light of day, let alone make eye contact.

doctor and was referred to CGH's A&E, where tests did not show anything wrong with him. What shocked doctors was his 90-degree

At 35, his he measur 1.65m fra sell chicke even thoug difficult to not think I also had a until he st

With nary ill, David

Typical treatment calls for anti-inflammatory medication, regular follow-up by a rheumatologist and physiotherapy to teach patients exercises to strengthen back muscles, improve posture, increase flexibility and range of motion, and techniques to enhance breathing.

As David's vomiting resulted from indigestion caused by his hunched back, surgery was the only way to correct his posture. "He was having trouble eating and breathing. If he didn't have surgery, he could have died," says Dr Chua.

"I hardly look at myself in the mirror and was shocked to see my back so hunched."

— Mr David Chua, 37, on his 90-degree curved spine

Four osteotomies (bone cutting surgeries) were performed — three smaller ones and one larger one which involved almost truncating the entire spinal column. Dr Chua had to make precise cuts in David's spinal column to remove the curved parts of his spine without injuring his spinal cord, and joining the cut ends with screws and rods. The single-stage surgery took

真实医疗档案HEALTH 口述: 蔡耀勋 (37岁, 新加坡工人) 笔录: 郑文学



资料提供:

蔡耀永医生
骨外科顾问医生
樟宜综合医院

照镜子才大吃一惊

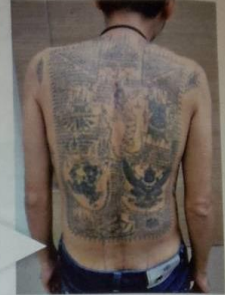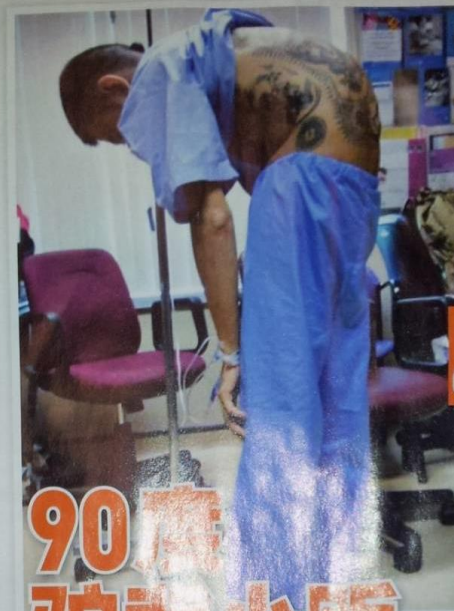
2011年,我妹妹察觉我的背部向前弯得厉害,就在那期间,我吃不下食物,即使勉强吞了也要吐出来。我吐出来的东西还是黑色的,妹妹说不行,拉着我去看医生。诊所医生为我稍作检查后,就写信给我去樟宜综合医院。

急诊部医生后来把我转到骨科作进一步检验。我的骨外科医生是蔡耀永。

蔡医生告诉我,我患的是强直性脊柱炎,是一种与遗传有关的脊柱病,主要症状是脊柱向后凸起,走路时身体自然要向前倾斜。这种疾病会越来越严重,除了胸部和腰背的脊椎骨,连接颈项部分的颈椎、连接脊柱骶骨的髋部也会受影响。

我从没有想到自己的驼背问题会那么严重,我也从来不会感觉腰背痛。

我在接受矫正手术前那天,突然看见大镜子里自己的模样,不禁大吃一惊,怎么我的驼背那么严重,已经弯成90度。



病人手术前后的照片

Q&A

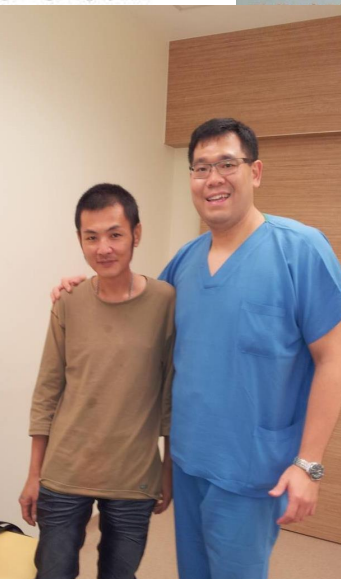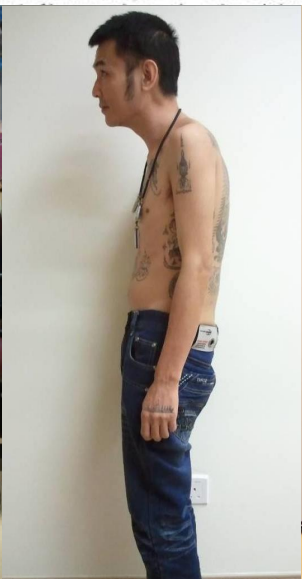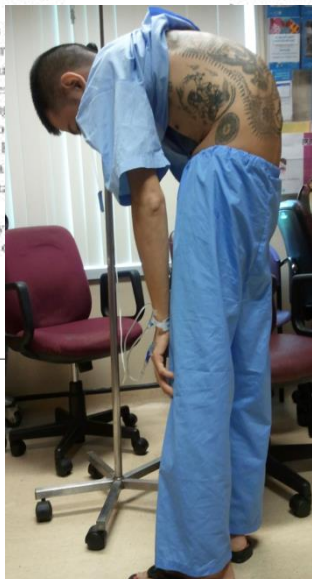问: 强直性脊柱炎是怎么回事?

强直性脊柱炎是以髋膝关节和脊柱附着点炎症为主要症状的疾病,患者多发生在10至40岁,平均发病年龄为25岁。男性较女性多见。遗传基因和环境因素在本病的发病中发挥作用。本病是一种慢性进展性疾病,难于彻底根治,应在专科医生指导下长期随访。

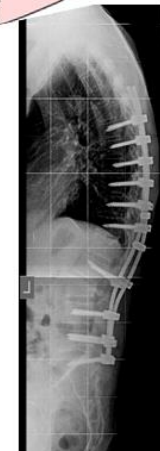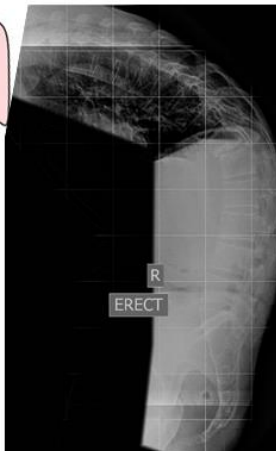
问: 你给病人作了什么手术?

我给他做了椎弓根减法,在脊柱切割了4个部分,一大三小,并用了20根钛金

90度 驼背小贼 手术后第二天 能挺直身体走路



Spinal Malalignment- Severe Kyphotic Deformity



位置。除了一般问题,切骨血,因此我并装上螺钉。均装好一根了。健康,手术骨在6至8个了。病人的他就不再